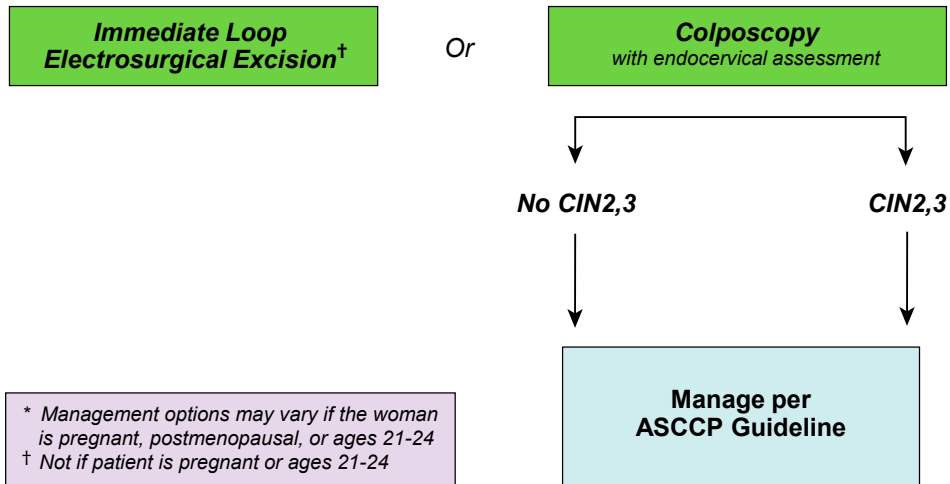


Management of Women with High-grade Squamous Intraepithelial Lesions (HSIL)*



© Copyright, 2013, American Society for Colposcopy and Cervical Pathology. All rights reserved. ASCCP