

ASCCP

The society for lower genital tract disorders since 1964.

Algorithms

Updated Consensus Guidelines for
Managing Abnormal Cervical Cancer
Screening Tests and Cancer Precursors

Introduction

Cytology

Since the publication of the 2006 consensus guidelines, new cervical cancer screening guidelines have been published and new information has become available which includes key cervical cancer screening and follow up, and cervical precancer management data over a nine year period among more than 1 million women cared for at Kaiser Permanente Northern California. Moreover, women under age 21 are no longer receiving cervical cancer screening and cotesting with high-risk HPV type assays, and cervical cytology is being used to screen women 30 years of age and older.

Therefore, in 2012 the American Society for Colposcopy and Cervical Pathology (ASCCP), together with its 24 partner professional societies, Federal agencies, and international organizations, began the process of revising the 2006 management guidelines. This culminated in the consensus

conference held at the National Institutes of Health in September 2012. This report provides updated recommendations for managing women with cytological abnormalities. A more comprehensive discussion of these recommendations and their supporting evidence was published in the *Journal of Lower Genital Tract Disease* and *Obstetrics and Gynecology* and is made available on the ASCCP website at www.asccp.org.

Histopathology

Appropriate management of women with histo-pathologically diagnosed cervical precancer is an important component of cervical cancer prevention programs. Although the precise number of women diagnosed with cervical precancer each year in the U.S. is not known, it appears to be a relatively common occurrence. In 2001 and 2006, the American Society for Colposcopy and Cervical Pathology and 28 partner professional societies, federal agencies, and international organizations, convened processes to develop and update consensus guidelines for the management of women with

cervical precancer. Since then, considerable new information has emerged about management of young women, and the impact of treatment for precursor disease on pregnancy outcomes. Progress has also been made in our understanding of the management of women with adenocarcinoma in-situ, also a human papillomavirus (HPV)—associated precursor lesion to invasive cervical adenocarcinoma. Therefore, in 2012 the ASCCP, together with its partner organizations, reconvened the consensus process of revising the guidelines. This culminated in the September 2012 Consensus Conference held at the National Institutes of Health. This report provides the recommendations developed for managing women with cervical precancer. A summary of the guidelines themselves—including the recommendations for managing women with cervical cytological abnormalities — are published in *JLGTD* and *Obstetrics & Gynecology*.

General Comments

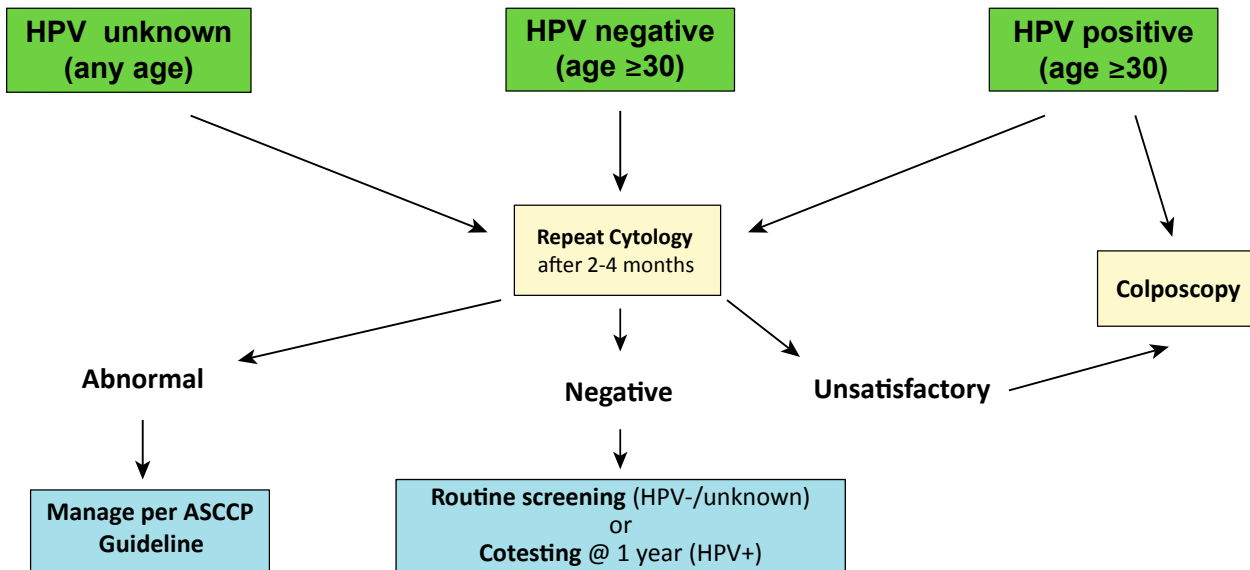
Although the guidelines are based on evidence whenever possible, for certain clinical situations limited high-quality evidence exists. In these situations the guidelines are based on consensus expert opinion. Guidelines should never be a substitute for clinical judgment. Clinical judgment should always be used when applying a guideline to an individual patient since guidelines may not apply to all patient-related situations. Finally, both clinicians and patients need to recognize that while most cases of cervical cancer can be prevented through a program of screening and management of cervical precancer, no screening or treatment modality is 100% effective and invasive cervical cancer can develop in women participating in such programs.

The 2001 Bethesda System terminology is used for cytological classification. This terminology utilizes the terms low-grade squamous intraepithelial lesion (LSIL) and high-grade squamous intraepithelial lesion (HSIL) to refer to low-grade lesions and high-grade cervical cancer precursors respectively. For managing cervical precancer, the histopathological classification is two-tiered applying the terms cervical intraepithelial neoplasia grade 1 (CIN1) to low-grade lesions and CIN2,3 to high-grade lesions. If using the 2012 Lower Anogenital Squamous Terminology (LAST), CIN1 is equivalent to histopathological LSIL and CIN2,3 is equivalent to histopathological HSIL. Please note that cytological LSIL is not equivalent to histopathological CIN1 and cytological HSIL

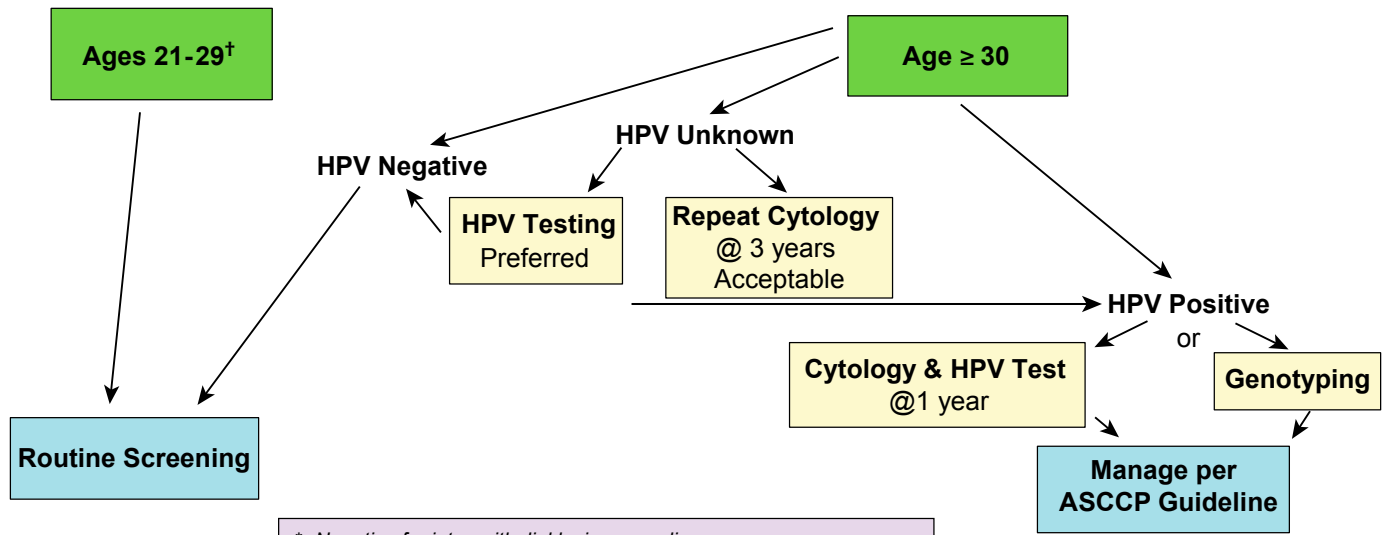
is not equivalent to histopathological CIN2,3. The current guidelines expand clinical indications for HPV testing based on studies using FDA-approved, validated HPV assays. Management decisions based on results using HPV tests not similarly validated may not result in outcomes intended by these guidelines. HPV testing should be restricted to high-risk (oncogenic) HPV types. Testing for low-risk (non-oncogenic) HPV types has no role in evaluating women with abnormal cervical cytological results. Therefore, whenever “HPV testing” is mentioned in the guidelines, it refers to testing for high-risk (oncogenic) HPV types only.

© Copyright, 2002, 2006, 2013 American Society for Colposcopy and Cervical Pathology. All rights reserved

Unsatisfactory Cytology

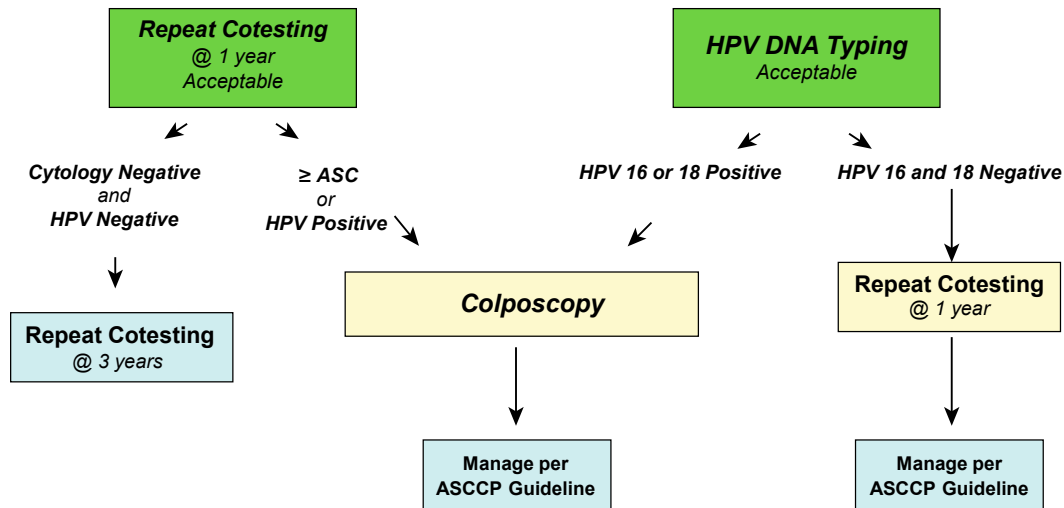


Cytology NILM* but EC/TZ Absent/Insufficient

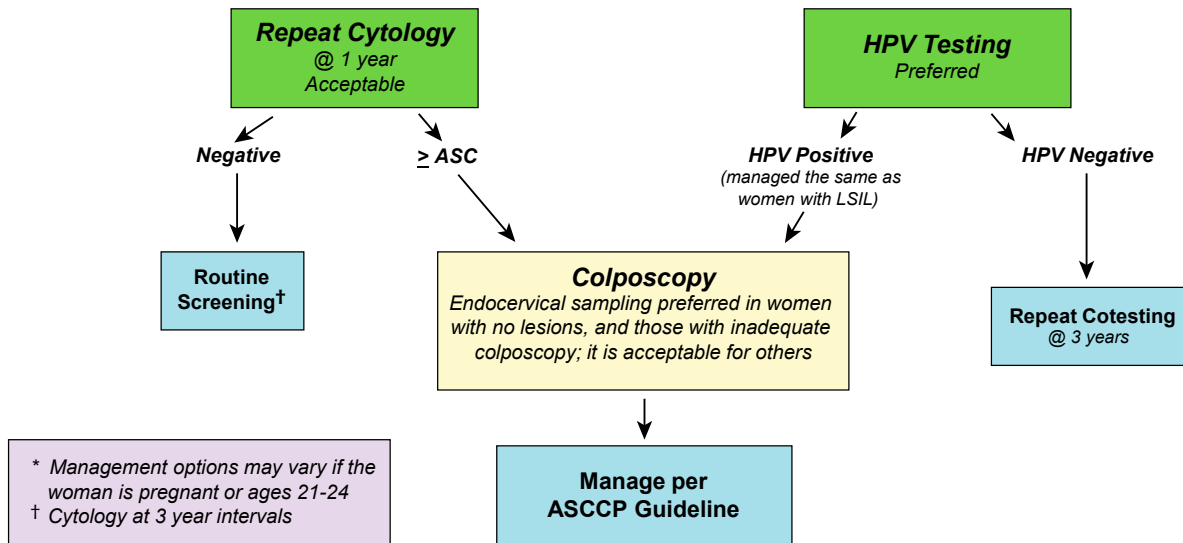


* Negative for intraepithelial lesion or malignancy
† HPV testing is unacceptable for screening women ages 21-29 years

Management of Women \geq Age 30, who are Cytology Negative, but HPV Positive

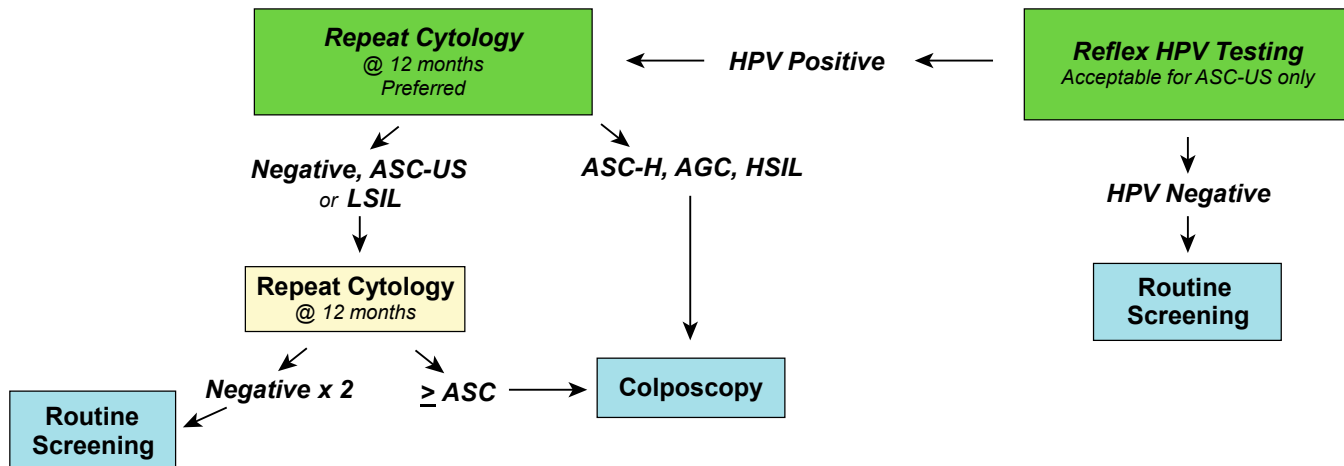


Management of Women with Atypical Squamous Cells of Undetermined Significance (ASC-US) on Cytology*

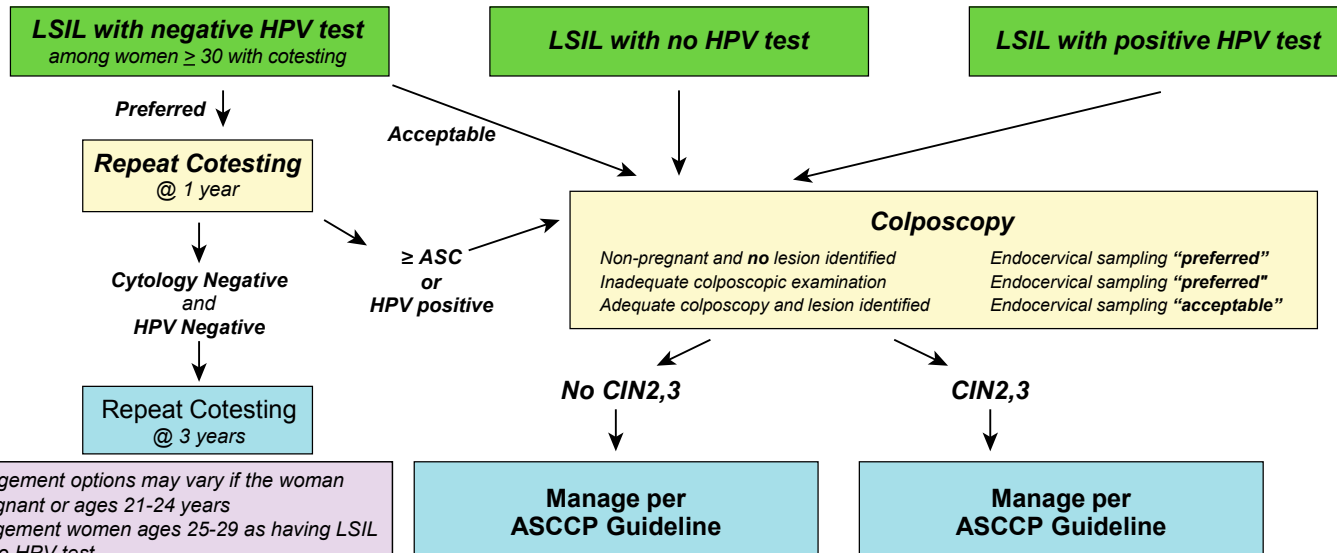


© Copyright, 2013, American Society for Colposcopy and Cervical Pathology. All rights reserved. ASCCP

Management of Women Ages 21-24 years with either Atypical Squamous Cells of Undetermined Significance (ASC-US) or Low-grade Squamous Intraepithelial Lesion (LSIL)



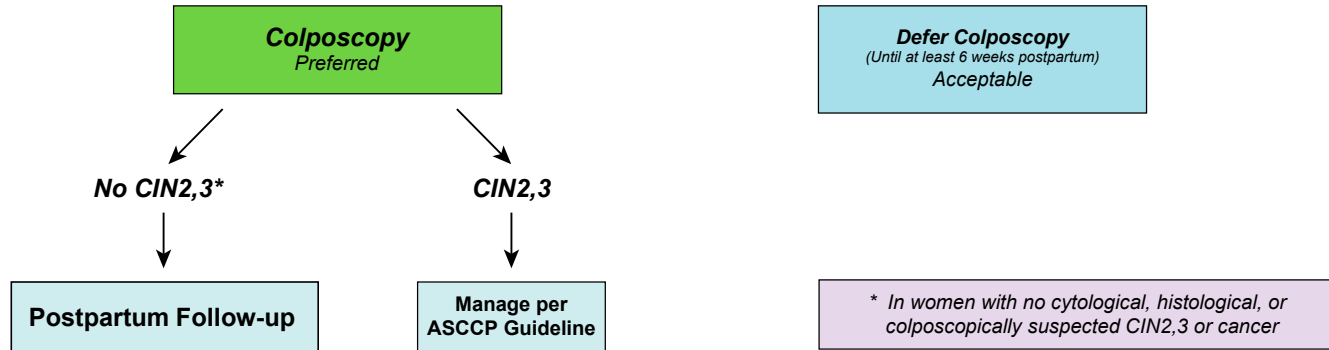
Management of Women with Low-grade Squamous Intraepithelial Lesions (LSIL)*†



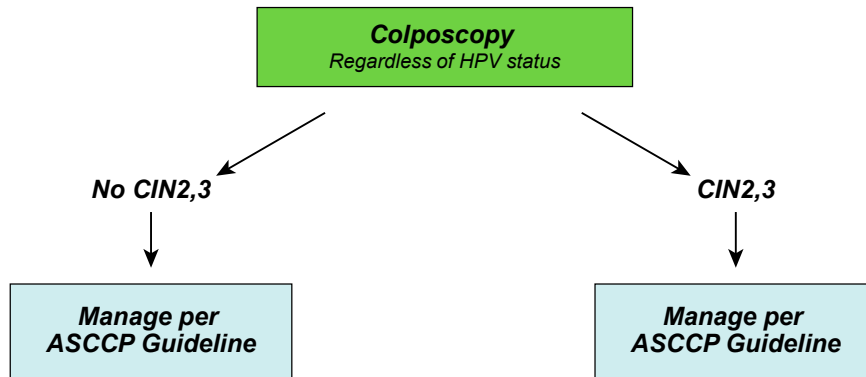
* Management options may vary if the woman is pregnant or ages 21-24 years

† Management women ages 25-29 as having LSIL with no HPV test

Management of Pregnant Women with Low-grade Squamous Intraepithelial Lesion (LSIL)

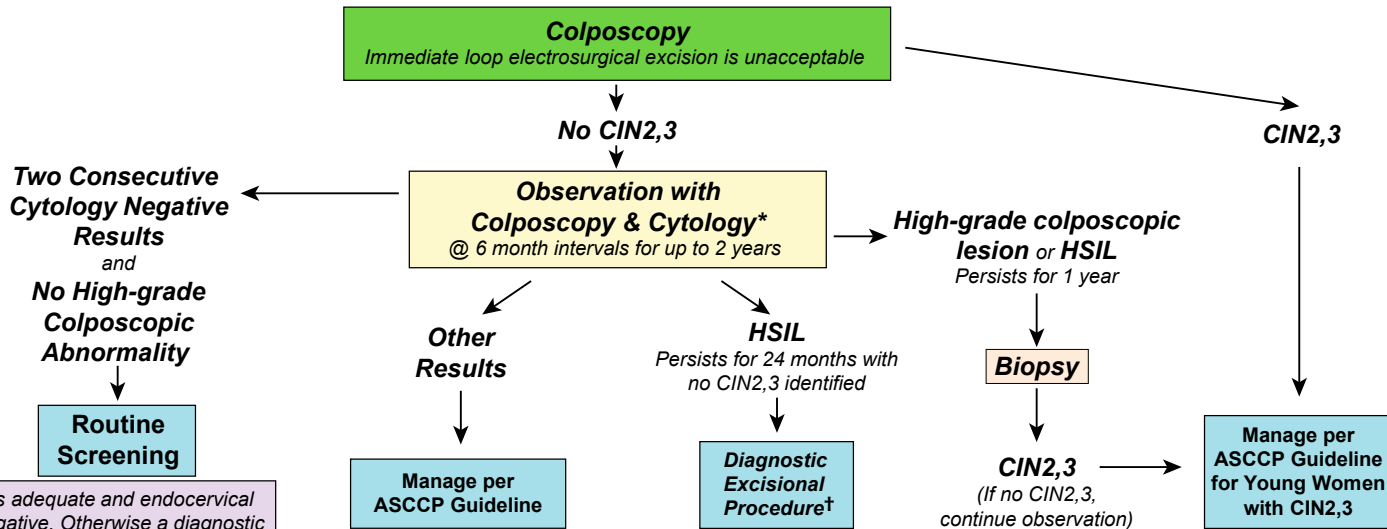


**Management of Women with Atypical Squamous Cells:
Cannot Exclude High-grade SIL (ASC-H)***



* Management options may vary if the woman is ages 21-24

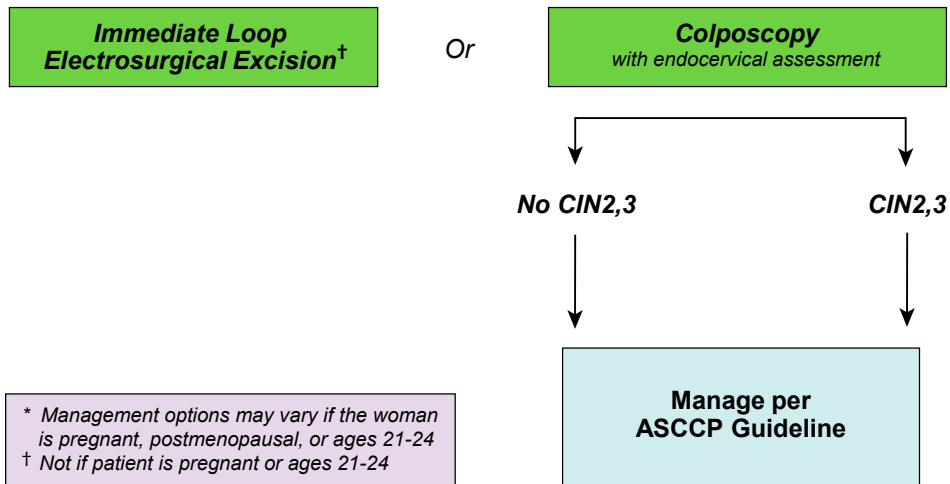
Management of Women Ages 21-24 yrs with Atypical Squamous Cells, Cannot Rule Out High Grade SIL (ASC-H) and High-grade Squamous Intraepithelial Lesion (HSIL)



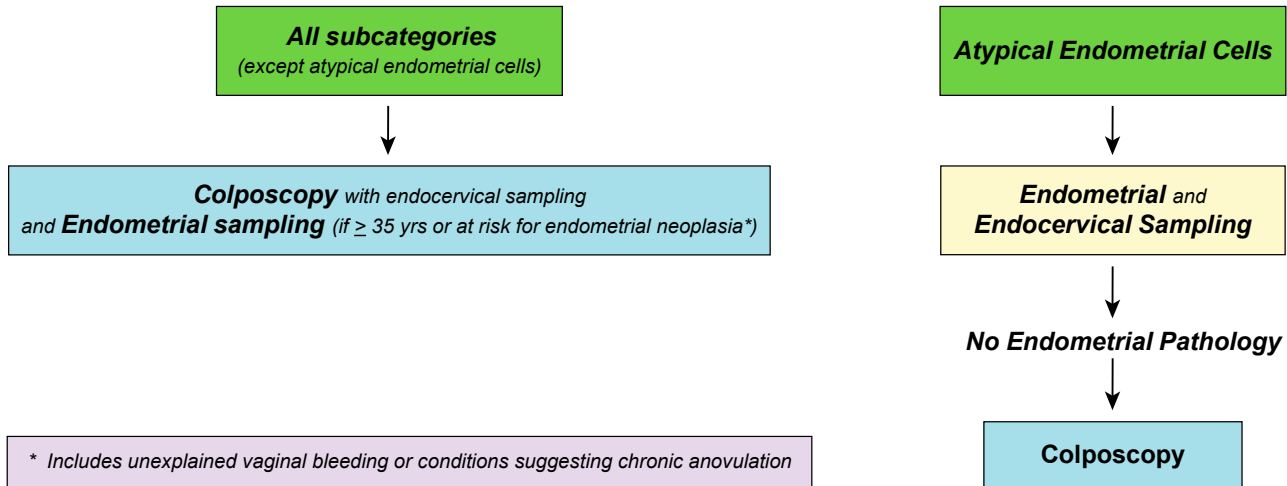
* If colposcopy is adequate and endocervical sampling is negative. Otherwise a diagnostic excisional procedure is indicated.

† Not if patient is pregnant

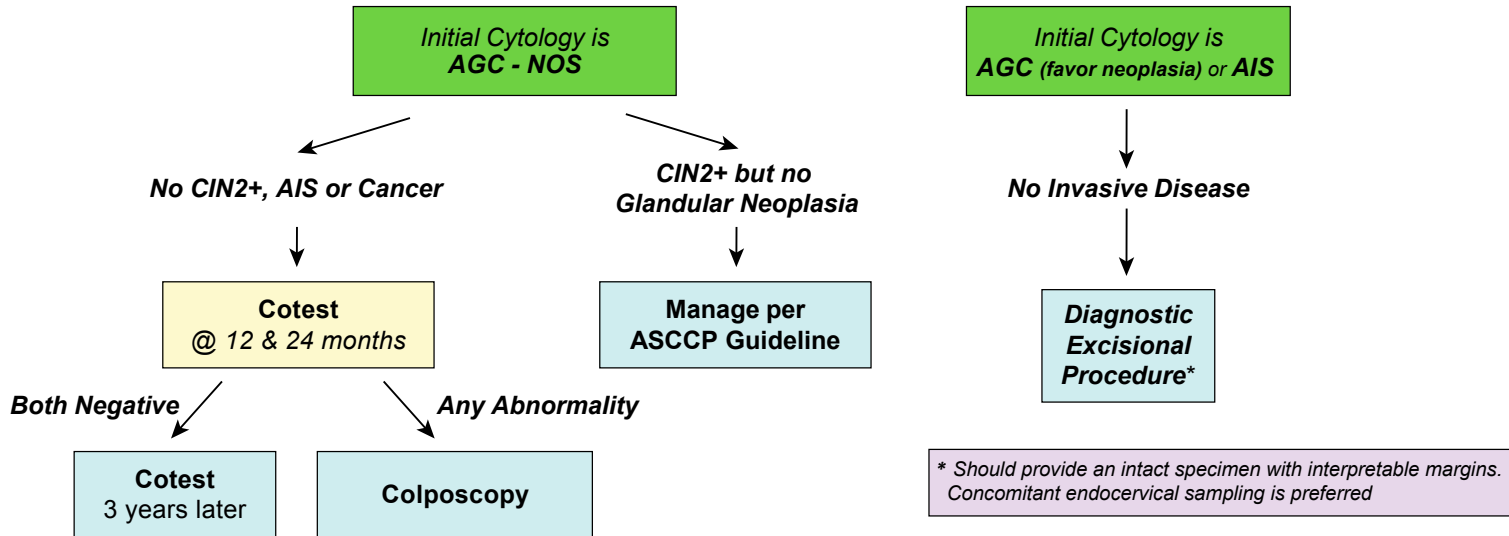
Management of Women with High-grade Squamous Intraepithelial Lesions (HSIL)*



Initial Workup of Women with Atypical Glandular Cells (AGC)

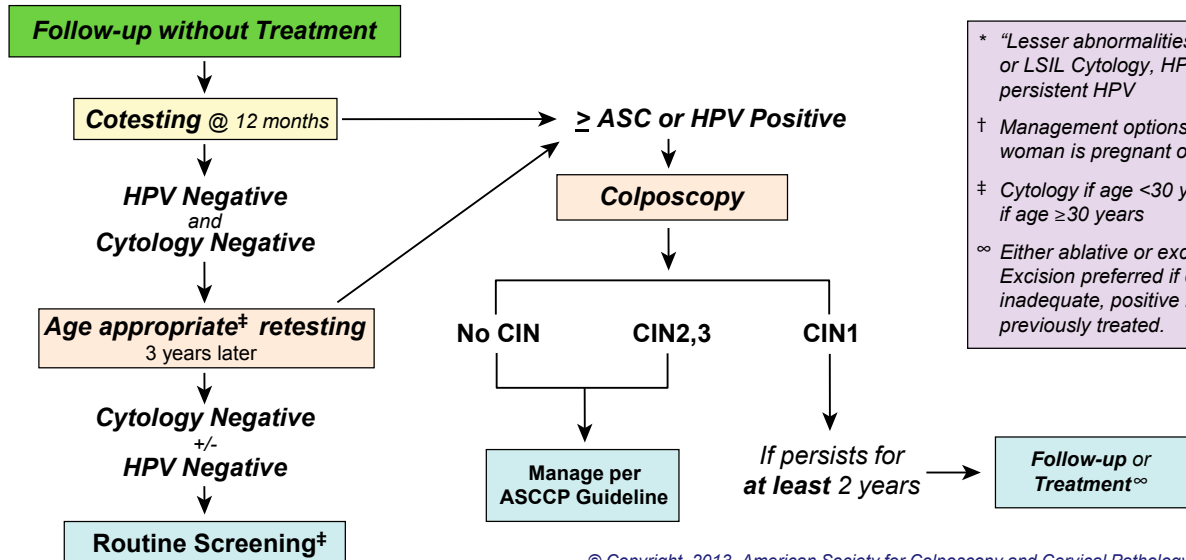


Subsequent Management of Women with Atypical Glandular Cells (AGC)



© Copyright, 2013, American Society for Colposcopy and Cervical Pathology. All rights reserved. **ASCP**

Management of Women with No Lesion or Biopsy-confirmed Cervical Intraepithelial Neoplasia — Grade 1 (CIN1) Preceded by “Lesser Abnormalities” *†



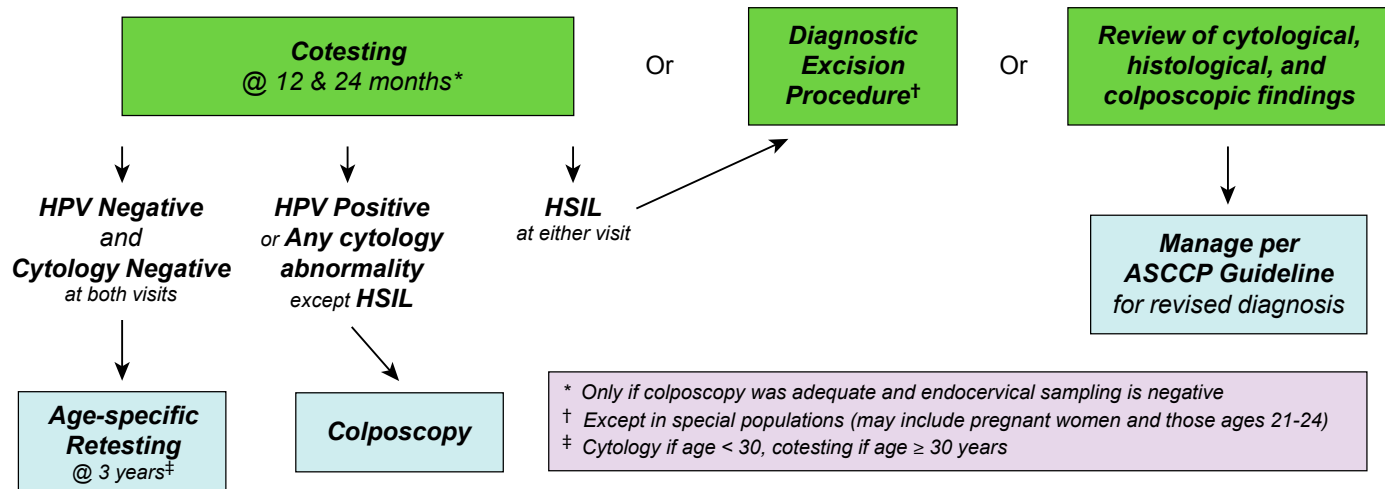
* “Lesser abnormalities” include ASC-US or LSIL Cytology, HPV 16+ or 18+, and persistent HPV

† Management options may vary if the woman is pregnant or ages 21-24.

‡ Cytology if age <30 years, cotesting if age ≥30 years

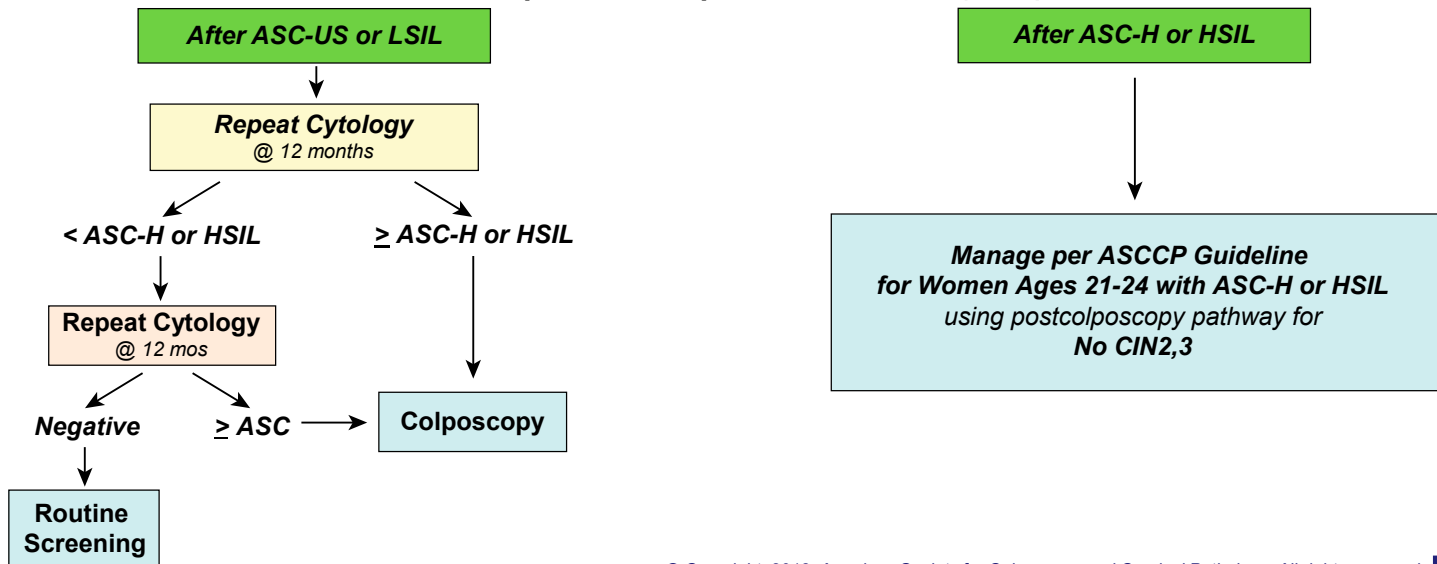
∞ Either ablative or excisional methods. Excision preferred if colposcopy inadequate, positive ECC, or previously treated.

Management of Women with No Lesion or Biopsy-confirmed Cervical Intraepithelial Neoplasia — Grade 1 (CIN1) Preceded by ASC-H or HSIL Cytology



© Copyright, 2013, American Society for Colposcopy and Cervical Pathology. All rights reserved. **ASCP**

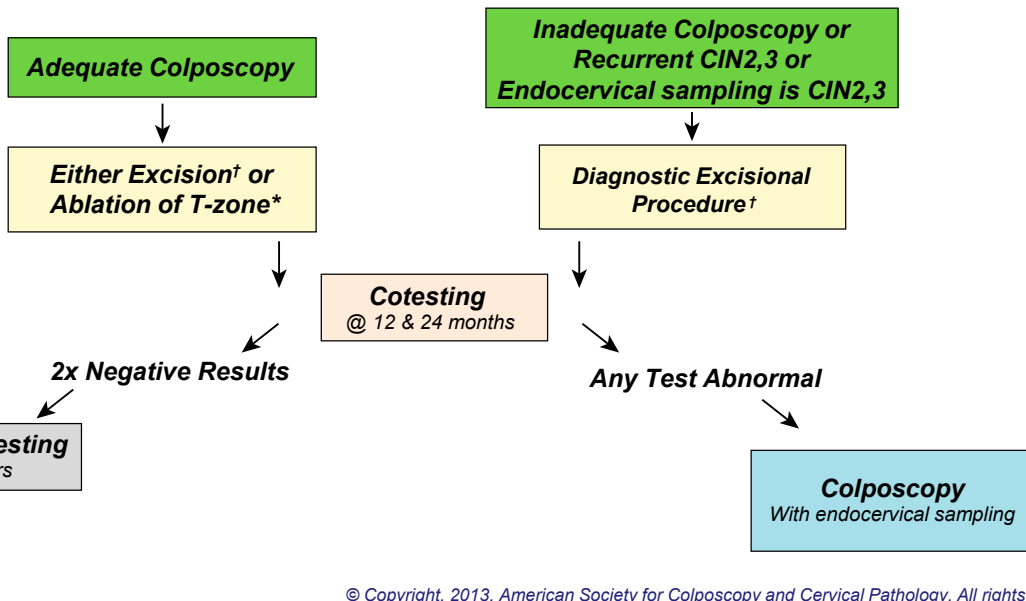
Management of Women Ages 21-24 with No Lesion or Biopsy-confirmed Cervical Intraepithelial Neoplasia — Grade 1 (CIN1)



Management of Women with Biopsy-confirmed Cervical Intraepithelial Neoplasia — Grade 2 and 3 (CIN2,3)*

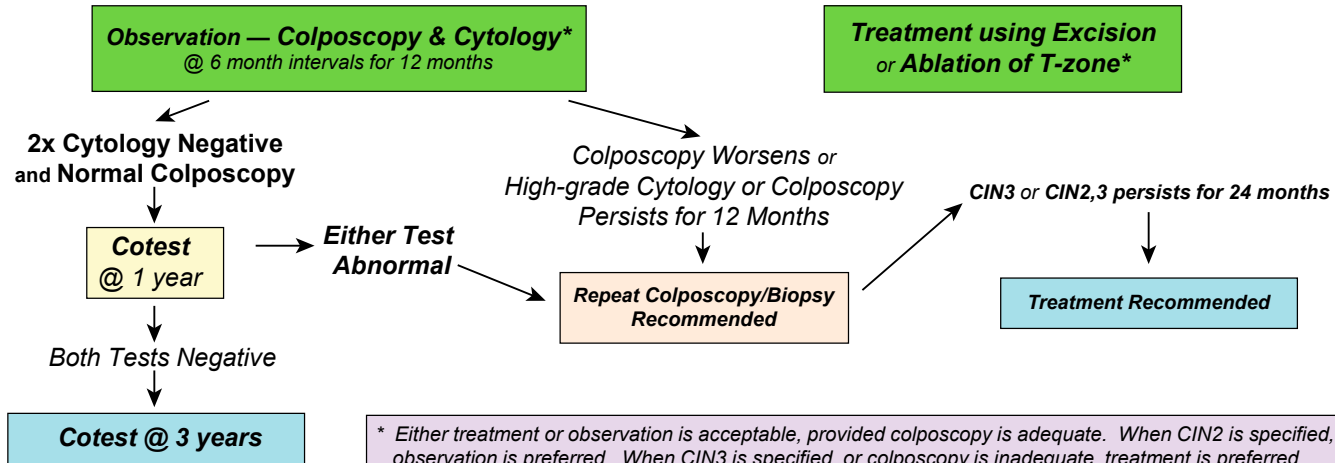
* Management options will vary in special circumstances or if the woman is pregnant or ages 21-24

† If CIN2,3 is identified at the margins of an excisional procedure or post-procedure ECC, cytology and ECC at 4-6mo is preferred, but repeat excision is acceptable and hysterectomy is acceptable if re-excision is not feasible.

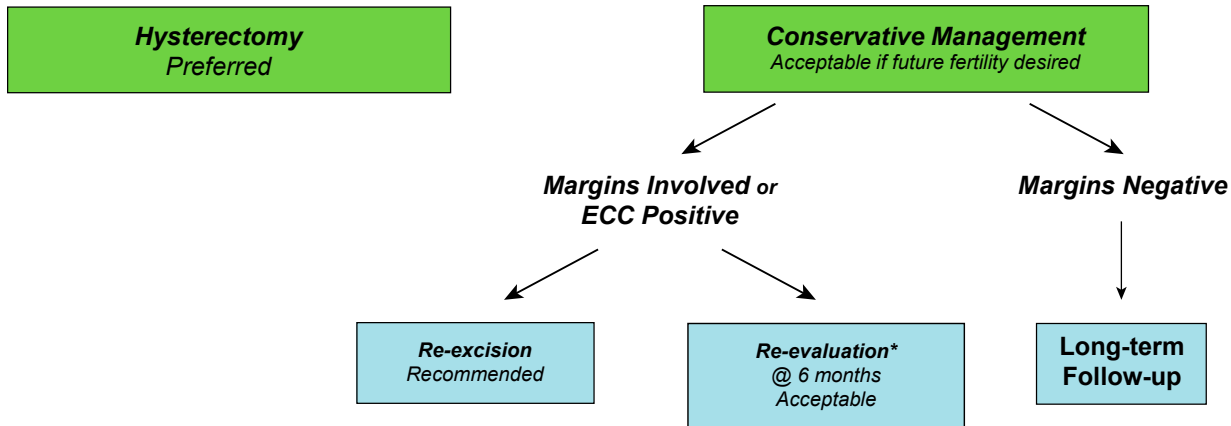


© Copyright, 2013, American Society for Colposcopy and Cervical Pathology. All rights reserved. ASCCP

Management of Young Women with Biopsy-confirmed Cervical Intraepithelial Neoplasia — Grade 2,3 (CIN2,3) in Special Circumstances*



Management of Women Diagnosed with Adenocarcinoma in-situ (AIS) during a Diagnostic Excisional Procedure



* Using a combination of cotesting and colposcopy with endocervical sampling

Interim Guidance for Managing Reports using the Lower Anogenital Squamous Terminology (LAST) Histopathology Diagnoses

***Low Grade Squamous
Intraepithelial Lesion
(LSIL)****



***Manage like
CIN1***

***High Grade Squamous
Intraepithelial Lesion
(HSIL)****



***Manage like
CIN2,3***

** Histopathology results only*

Definitions

Terms Utilized in the Consensus Guidelines

- **Colposcopy** is the examination of the cervix, vagina, and, in some instances the vulva, with the colposcope after the application of a 3-5% acetic acid solution coupled with obtaining colposcopically-directed biopsies of all lesions suspected of representing neoplasia.
- **Endocervical sampling** includes obtaining a specimen for either histopathological evaluation using an endocervical curette or a cytobrush or for cytological evaluation using a cytobrush.
- **Endocervical assessment** is the process of evaluating the endocervical canal for the presence of neoplasia using either a colposcope or endocervical sampling.
- **Diagnostic excisional procedure** is the process of obtaining a specimen from the transformation zone and endocervical canal for histopathological evaluation and includes laser conization, cold-knife conization, loop electrosurgical excision procedure (LEEP), and loop electrosurgical conization.
- **Adequate colposcopy** indicates that the entire squamocolumnar junction and the margin of any visible lesion can be visualized with the colposcope.
- **Endometrial sampling** includes obtaining a specimen for histopathological evaluation using an endometrial aspiration or biopsy device, a “dilatation and curettage” or hysteroscopy.

Acknowledgments

These guidelines were developed with funding from the American Society for Colposcopy and Cervical Pathology (ASCCP). The contents are solely the responsibility of the authors and the ASCCP.

L. Stewart Massad, M.D., Washington University School of Medicine, St. Louis, MO; Mark H. Einstein, M.D., Albert Einstein College of Medicine, Bronx, NY; Warner K. Huh, M.D., University of Alabama School of Medicine, Birmingham, AL; Hormuzd A. Katki, Ph.D., Division of Cancer Epidemiology and Genetics, National Cancer Institute, Bethesda, MD; Walter K. Kinney, M.D., The Permanente Medical Group, Sacramento, CA; Mark Schiffman, M.D., Diane Solomon, M.D., Division of Cancer Prevention, National Cancer Institute, Bethesda, MD; Nicolas Wentzensen, M.D., Division of Cancer Epidemiology and Genetics, National Cancer Institute, Bethesda, MD; Herschel W. Lawson, M.D., Emory University School of Medicine, Atlanta, GA, on behalf of the 2012 ASCCP Consensus Guidelines Conference

All copyright permission requests should be sent to the ASCCP National Office, 1530 Tilco Dr., Ste. C, Frederick, MD 21704

ASCCP

1530 Tilco Drive, Suite C

Frederick, MD 21704

(301) 733-3640 (telephone)

(800) 787-7227 (toll free)

(240) 575-9880 (fax)

For more information, or to order
additional copies, please email:
administrator@asccp.org



The society for lower genital
tract disorders since 1964.

www.asccp.org/Guidelines